

Left Unilateral Neglect as a Disconnection Syndrome

Paolo Bartolomeo^{1,2,3}, Michel Thiebaut de Schotten^{1,3} and Fabrizio Doricchi^{4,5}

¹INSERM Unit 610, Hôpital de la Salpêtrière, F-75013 Paris, France, ²Department of Neurology, Assistance Publique - Hôpitaux de Paris (AP-HP), Hôpital de la Salpêtrière, Paris, France, ³Université Pierre et Marie Curie-Paris 6, Paris, France, ⁴Centro Ricerche di Neuropsicologia, Fondazione Santa Lucia—Istituto di Ricovero e Cura a Carattere Scientifico, 00179 Roma, Italy and ⁵Dipartimento di Psicologia 39, Università degli Studi di Roma “La Sapienza,” Roma, Italy

Unilateral spatial neglect is a disabling neurological condition that typically results from right hemisphere damage. Neglect patients are unable to take into account information coming from the left side of space. The study of neglect is important for understanding the brain mechanisms of spatial cognition, but its anatomical correlates are currently the object of intense debate. We propose a reappraisal of the contribution of disconnection factors to the pathophysiology of neglect based on a review of animal and patient studies. These indicate that damage to the long-range white matter pathways connecting parietal and frontal areas within the right hemisphere may constitute a crucial antecedent of neglect. Thus, neglect would not result from the dysfunction of a single cortical region but from the disruption of large networks made up of distant cortical regions. In this perspective, we also reexamined the possible contribution to neglect of interhemispheric disconnection. The reviewed evidence, often present in previous studies but frequently overlooked, is consistent with the existence of distributed cortical networks for orienting of attention in the normal brain, has implications for theories of neglect and normal spatial processing, opens perspectives for research on brain-behavior relationships, and suggests new possibilities for patient diagnosis and rehabilitation.

Keywords: attention, brain lesions, perceptual disorders, spatial cognition, white matter fiber pathways

No wonder Lashley thought the whole brain was involved in mental tasks. It was not the whole brain, but a widely dispersed network of quite localized neural areas
Michael I. Posner (2005, p. 239)

Introduction

Patients with right hemisphere damage often show signs of left unilateral neglect, an inability to take into account information coming from the left side of space (Mesulam 1985; Heilman et al. 1993; Bartolomeo and Chokron 2001, 2002; Vallar 2001; Parton et al. 2004). Neglect patients do not eat from the left part of their dish, they bump with their wheelchair into obstacles situated on their left, and when questioned from the left side they may either fail to answer or respond to a right-sided bystander. When presented with bilateral stimuli, they may immediately look toward the rightmost stimulus, as if their attention were “magnetically” attracted (Gainotti et al. 1991). On visuospatial testing, they omit targets on the left in search tasks, deviate rightward when bisecting horizontal lines, and do not copy the left part of drawings. This neurological condition is a significant source of handicap and disability for patients and entails a poor functional outcome. A better understanding of neglect is thus required both on clinical grounds, for purposes

of diagnosis and rehabilitation, and in order to comprehend the brain mechanisms of attention and spatial processing. Unfortunately, however, despite decades of research there are still important disagreements on the interpretation of the neglect syndrome, even on basic matters such as its lesional basis. This question constitutes the specific focus of the present review.

Most studies devoted to the anatomical correlates of neglect indicate the temporal-parietal junction (TPJ) and the inferior parietal lobule (IPL) (Vallar 2001; Mort et al. 2003), consistent with the known role of posterior parietal cortex in spatial attention (Colby and Goldberg 1999; Gitelman et al. 1999; Corbetta and Shulman 2002). In contrast with this view, another line of findings implicated more rostral portions of the superior temporal gyrus (Karnath et al. 2001, 2004), emphasizing the role of the ventral visual stream in spatial awareness originally hypothesized by Milner and Goodale (1995). In addition, damage to several other brain structures has been reported to determine neglect, including the thalamus, the basal ganglia, and the dorsolateral prefrontal cortex (Vallar 2001; Karnath et al. 2002).

However, at variance with interpretations of neglect stressing the role of damage to local brain modules, it has long been proposed that attentional spatial processes that may be disrupted in neglect do not result from the activity of single-brain areas but rather emerge from the interaction of large-scale networks (Mesulam 1981; Heilman et al. 1993). If so, then damage to the connections making up these networks is expected to impair their integrated functioning and consequently to bring about signs of neglect. Consistent with this prediction, here we review accumulating evidence that long-lasting signs of left unilateral neglect may also result from the important influence of intra- and interhemispheric disconnection.

Intrahemispheric Disconnection

Frontoparietal Networks of Spatial Attention

Within each hemisphere, large-scale cortical networks coordinate the operations of spatial attention (Mesulam 1981; Posner and Petersen 1990; LaBerge 2000; Corbetta and Shulman 2002). Important components of these networks include the dorsolateral prefrontal cortex and the posterior parietal cortex. Physiological studies indicate that these 2 structures show interdependence of neural activity. During memory-guided saccades, cooling of parietal neurons engenders changes in neural activity in prefrontal neurons, and vice versa (Chafee and Goldman-Rakic 2000). Not surprisingly, in the monkey, these 2 structures are directly and extensively interconnected (Selemon and Goldman-Rakic 1988; Morecraft et al. 1993). Several distinct frontoparietal long-range pathways have been identified (Petrides and Pandya 2002; Schmahmann and Pandya 2006).

These pathways include the arcuate fasciculus (AF), the superior longitudinal fasciculus (SLF), and the frontooccipital fasciculus (FOF). The AF links the caudal portions of the temporal lobe, at the junction with the parietal lobe, with the dorsal portions of the areas 8, 46, and 6 in the frontal lobe (Schmahmann and Pandya 2006). Within the SLF, 3 distinct branches and course (Fig. 1; Petrides and Pandya 2002; Schmahmann and Pandya 2006). The SLF I links the superior parietal region and the adjacent medial parietal cortex with the supplementary and premotor areas in the frontal lobe. The SLF II originates in the caudal inferior parietal lobe (corresponding to the human angular gyrus) and the occipitoparietal area and projects to the dorsolateral prefrontal cortex. The SLF III connects the rostral portion of the inferior parietal lobe (homologous to the human supramarginal gyrus) with the ventral premotor area 6, the adjacent area 44, the frontal operculum, and the area 46. The FOF links the medial preoccipital area PO, the lateral-dorsal occipital area DP, the medial parietal area PGM, the caudal cingulate gyrus, and the caudal IPL to the dorsal premotor (area 6) and the dorsal prefrontal cortices (areas 8, 9, and 46) (Schmahmann and Pandya 2006). Rizzolatti and Matelli (2003) proposed to dissociate the dorsal cortical visual stream (see Mishkin et al. 1983; Milner and Goodale 1995) into 2 components, a dorsodorsal stream, which controls actions “on line” and whose damage leads to optic ataxia, and a ventrodorsal stream, implicated in space perception and action understanding. In this framework, FOF and SLF II may be considered to connect, respectively, the dorsodorsal and the ventrodorsal cortical networks (Schmahmann and Pandya 2006). Although it is not a frontoparietal pathway, the inferior longitudinal fasciculus (ILF) may also be relevant here because its lesion has been implicated in neglect (Leibovitch et al. 1998; Bird et al. 2006). In the monkey, the ILF originates in the ventral lateral and ventral preoccipital areas and runs in the depth of the temporal lobe to terminate in the superior temporal sulcus, the inferior temporal gyrus, and other temporal areas; moreover, it connects the caudal part of the cingulate gyrus, the IPL, and the superior temporal gyrus (STG) to the parahippocampal gyrus (Schmahmann and Pandya 2006).

Diffusion tensor imaging (DTI), a new technique to map the course of white matter tracts in the living human brain (Basser et al. 1994), has demonstrated a similar organization of frontoparietal pathways in humans (Catani et al. 2002; Makris et al. 2005; Rushworth et al. 2005), although the identification of the cortical terminations remains uncertain due to the technical limitations of the DTI method.

Frontoparietal Disconnection and Spatial Neglect

How is visuospatial processing affected by damage to these frontoparietal networks? In a groundbreaking study in the monkey, Gaffan and Hornak (1997) showed that severe neglect may arise after a unilateral section of the white matter between the fundus of the intraparietal sulcus and the lateral ventricle, interrupting long-range communication pathways between the parietal and the frontal lobes. When showed several horizontally arranged stimuli, neglect monkeys often omitted to respond to targets contralateral to the lesion, choosing instead an ipsilateral distractor. Interestingly, in this study monkeys demonstrated little, if any, contralateral neglect after isolated ablations of the frontal cortex and the posterior parietal cortex or even after

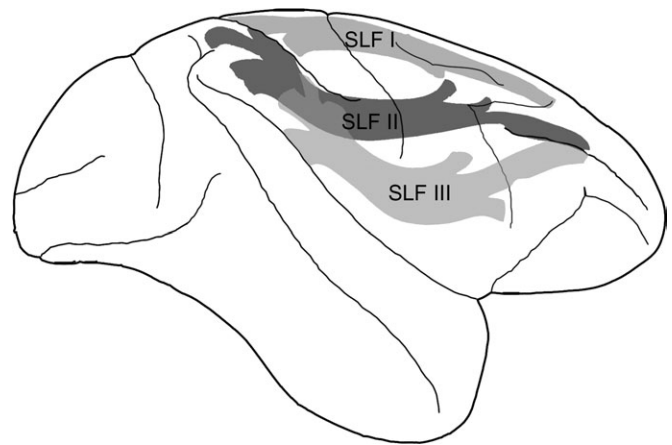


Figure 1. Schematic depiction of the 3 branches of the SLF in the monkey brain according to Schmahmann and Pandya (2006).

a combined lesion of both of these structures. The monkeys with neglect also had clear impairments in everyday activities such as visual searching for food in free vision in the home cage. When offered 2 handfuls of food by an observer, they failed to find the food in the observer’s hand that was contralateral to the monkey’s lesion. This was in marked contrast to the monkeys with hemianopia alone that had efficient visual searching which compensated for their hemianopia in free vision (Gaffan D, personal communication, 2006). Thus, disconnection really proved crucial to observe neglect in monkeys in this study (for analogous results obtained in rodents, see Burcham et al. 1997; Reep et al. 2004).

Importantly, analogous findings were reported in different studies in human patients. Using computed tomography scans and single photon emission computed tomography, Leibovitch et al. (1998) investigated the anatomical correlates of neglect in a large sample of right brain-damaged patients not selected for the presence or absence of concomitant visual field defects. These authors found that the main correlate of chronic neglect was the combined lesion involvement and hypofunctioning of fibers connecting the parietal and temporal lobes (ILF), as well as those linking the parietal and frontal lobes (SLF), loaded in the white matter beneath the TPJ.

More recently, Doricchi and Tomaiuolo (2003) made a further step and disentangled the contribution of SLF and ILF disconnection to spatial neglect. In their study, lesion overlap was mapped in a sample of chronic neglect patients without visual field defects. Patients were further divided in 2 subgroups based on whether the lesion involved or spared the basal ganglia. In both subgroups, areas of maximal lesion overlap were found in the SLF beneath the rostral sector of the supramarginal gyrus. This finding revealed that, in humans, damage limited to frontoparietal connections in the SLF is sufficient to contribute to the development of chronic neglect. The authors concluded that while “a brain damage affecting circumscribed portions of the IPL could. . . disrupt only a subset of those different spatial abilities that, with different emphasis and by different authors, are currently considered to be specifically defective in neglect patients, . . . disconnection of the parietal-frontal spatial attentional network. . . might render neglect more persistent by extensively compromising the sensory-motor mapping of the contralesional space even in those patients who, suffering only partial damage of the functionally

heterogeneous IPL-TPJ area, would otherwise show more selective (and perhaps transitory) parietal related spatial deficits” (p. 2242).

More compelling and direct evidence stressing the importance of frontoparietal disconnection in neglect came from a recent study employing intraoperative electrical stimulation in human patients (Thiebaut de Schotten et al. 2005). During brain surgery for resection of low-grade gliomas, neurosurgeons often awaken patients in order to assess the functional role of restricted brain regions so that the extent of the excision can be maximized without provoking cognitive impairments. Patients perform cognitive tasks, such as counting or naming, while the surgeon temporarily inactivates restricted regions around the tumor, using electrical stimuli. If the patient stops talking or produces incorrect responses, the surgeon avoids removing the stimulated region. This technique allows researchers to map cognitive functions in humans with unrivaled spatiotemporal resolution (~5 mm by 4 s). Thiebaut de Schotten et al. (2005) asked 2 patients with gliomas in the right temporoparietal region to mark the midpoint of 20-cm horizontal lines (a typical neglect task; Azouvi et al. 2002) while being stimulated. Electrical stimulation of the right IPL or the caudal STG, but not of its more rostral portions, determined rightward deviations on line bisection.

However, the strongest shifts occurred when one of the patients was stimulated subcortically. Fiber tracking using DTI identified the stimulated site as the likely human homologue of the SLF II (in the original article, which was published before the atlas of Schmahmann and Pandya became available, the pathway was incorrectly labeled as FOF; this, however, does not hamper the main point made by Thiebaut de Schotten and co-workers that damage to the frontoparietal pathways is important to produce neglect), consistent with the postulated role of this pathway in space perception (Rizzolatti and Matelli 2003; Schmahmann and Pandya 2006). Thus, there is a remarkable consistency between the behavioral consequences of frontoparietal disconnection in humans and monkeys, despite the fact that different behavioral tests were used: line bisection (Thiebaut de Schotten et al. 2005) or target cancellation (Doricchi and Tomaiuolo 2003) in humans and target search in monkeys (Gaffan and Hornak 1997). This convergence of results strongly suggests a similar organization of space-processing mechanisms across the 2 species. The demonstration of the role of frontoparietal disconnections in neglect supports models of neglect postulating an impairment of large-scale right hemisphere networks (Mesulam 1999), including prefrontal, parietal, and cingulate components. The parietal component could determine the perceptual salience of extrapersonal objects, whereas the frontal component might be implicated in the production of an appropriate response to behaviorally relevant stimuli (Mesulam 1999), in the online retention of spatial information (Husain and Rorden 2003) or in the focusing of attention on salient items through reciprocal connections to more posterior regions (Petrides and Pandya 2002). We also note that, as a consequence of frontoparietal disconnection, inaccurate or slowed communication between posterior and anterior brain regions, whether coupled or not with a general deficit in responding to unattended stimuli, might delay the information transfer from sensory-related areas to response-related regions to the point of exceeding an elapse of time after which this information is no longer useful for affecting behavior (Bartolomeo and Chokron 2002).

Reappraisal of Previous Lesion Overlap Studies

To explore the consistency of the above reviewed results with previous evidence from vascular patients, we plotted on a standardized brain the subcortical lesions of the stroke patients with neglect from the lesion overlapping studies that contained sufficient details (Doricchi and Tomaiuolo 2003; Mort et al. 2003; Karnath et al. 2004; Corbetta et al. 2005). Long-range connections were visualized using fiber tracking (Thiebaut de Schotten et al. 2006) (see Supplementary Material). Most interestingly, neglect patients' lesions invariably overlapped at or near the subcortical long-range pathways linking the parietal to the frontal lobes (Fig. 2). The same meta-analysis revealed the presence of an important lesion overlap in the white matter frontoparietal connections in the study by Karnath et al. (2004). This overlap shows striking resemblance with the lesion overlap documented by Doricchi and Tomaiuolo (2003) in the same area, indicating that in the sample of patients studied by Karnath et al. (2004), lesion overlap in the STG was not selective and that neglect could have been due to frontoparietal disconnection rather than STG damage.

Further Evidence on Frontoparietal Disconnection in Neglect

In a recent group study on 52 right brain-damaged patients with vascular lesions, Committeri et al. (2007) investigated the anatomical correlates of personal neglect (i.e., neglect concerning the patient's own body) and extrapersonal neglect (concerning the space external to the patient's body). Committeri et al. concluded that personal neglect is due to lesion involvement of the supramarginal gyrus in the parietal lobe, whereas extrapersonal neglect results from damage of more ventral areas including the STG and the inferior frontal gyrus (IFG).

In a first series of comparisons, the authors made voxel-by-voxel subtractions between 1) patients with extrapersonal neglect (whether isolated or in combination with personal neglect) versus patients with pure personal neglect or no neglect at all; 2) patients with personal neglect (whether isolated or in combination with extrapersonal neglect) versus patients with pure extrapersonal neglect or no neglect. The results of these subtractions are reported in their Figure 2. In the first row of axial slices, a distinct area of overlap is clearly present in the white matter of the axial slice $z = +28$. We found that this spot is perfectly centered on the SLF on the matching Talairach template and is only 9 mm caudal and 1 mm superior to the maximum lesion overlap previously found by Doricchi and Tomaiuolo (2003) in a group of patients showing extrapersonal neglect on both line-bisection and multiple-item cancellation tasks (see Supplementary Fig. 2).

In a second series of subtractions, Committeri et al. compared patients with pure extrapersonal neglect or pure personal neglect with patients without neglect. Also in this case, a similar maximum lesion overlap on the SLF was found in patients with pure extrapersonal neglect (see the axial slice $z = +28$ in the third row of their Fig. 2). These anatomical findings went probably unnoticed because for the quantitative analysis, Committeri et al. considered the percentage of white matter damaged within 3 ample regions of interest: the centrum semiovale, the supralenticular and sublenticular corona radiata, and the external and internal capsulae. They found that the white matter immediately dorsal (supralenticular corona radiata and centrum semiovale) and ventral (sublenticular corona radiata) to

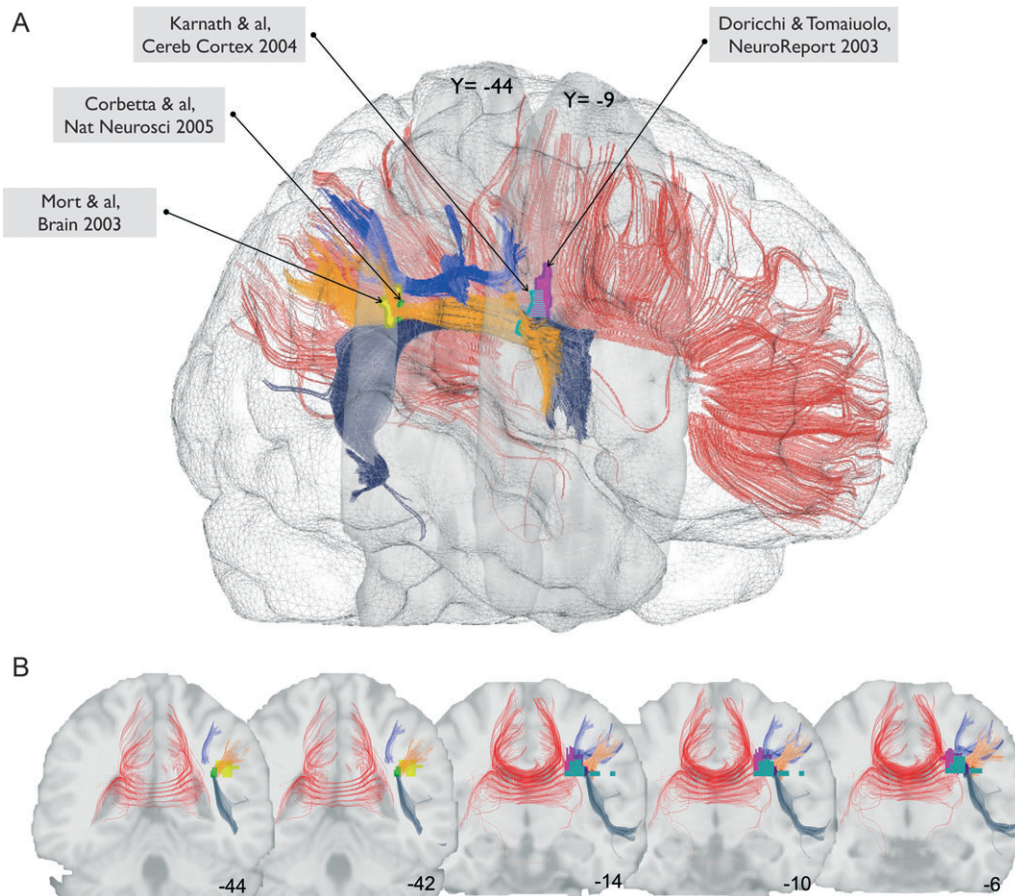


Figure 2. Lateral view (A) and coronal sections (B) of a normalized brain showing a 3-dimensional reconstruction of white matter pathways (red, corpus callosum; dark blue, AF; orange, SLF III; blue, SLF II) and the maximum overlap of neglect patients' subcortical lesions from 4 studies (pink, Doricchi and Tomaiuolo 2003; yellow, Mort et al. 2003; light blue, Karnath et al. 2004; green, Corbetta et al. 2005). See Supplementary Material for methods.

the insula was significantly more damaged in patients with extrapersonal neglect and that the white matter underlying the supramarginal gyrus was more damaged in patients with personal neglect. However, with respect to a more precise anatomical localization of these areas, the higher spatial resolution provided by voxel-by-voxel subtractions reported in their Figure 2 is instructive and unequivocal in indicating specific damage of white matter fasciculi linking parietal and frontal areas in patients with extrapersonal neglect. With reference to the distinct branches of the SLF identified in the monkey by Schmahmann and Pandya (2006) (see Supplementary Fig. 1 and Supplementary Material), we found that the maximum lesion overlap found by Committeri et al. locates itself at the boundary between the likely human homologous of SLF II and SLF III (see Supplementary Fig. 2). Thus, the involvement of dorsal SLF underneath the central sulcus documented by Doricchi and Tomaiuolo (2003) cannot be merely attributed to the presence of concomitant and undetected personal neglect that, as proposed by Committeri et al. in the discussion section, would have shifted the lesion overlap dorsally with respect to more ventral areas which, in their proposal, would subserved awareness of the extrapersonal space.

In a third analysis of their data, Committeri et al. used voxel-based lesion-symptom mapping (VLSM; see Bates et al. 2003). For each voxel, patients were divided into 2 groups according to whether or not their lesion affected that voxel. Scores for

extrapersonal and personal neglect were then compared for these 2 groups, yielding a *t*-statistics for each voxel and a corresponding *t*-test-based statistical map for the entire voxel-based brain volume. Also in this case, white matter involvement was present for extrapersonal neglect in fibers feeding the frontal eye field (first row of their Fig. 4, sagittal slice $x = +36$; a more ventral white matter involvement is evident in axial slice $z = +20$) as well as for personal neglect (second row of their Fig. 4, axial slice $z = +32$ and sagittal slice $z = +36$). VLSM analysis also allows researchers to evaluate the similarity between the *t*-test-based statistical maps by calculating the correlations between the *t*-scores of personal and extrapersonal neglect for each voxel (Bates et al. 2003). A positive correlation for one voxel suggests that this voxel performs a core function common to both types of deficit (Bates et al. 2003). Committeri et al. obtained a strong positive correlation of 0.84 (reflecting 70% of overlap in the variance) for the IFG (see Husain and Kennard 1996), the posterior insular-opercular temporal-parietal cortex, and most importantly, the white matter underlying the central sulcus (see Doricchi and Tomaiuolo 2003). Therefore, also the VLSM analysis demonstrated that this region of the white matter is implicated in a core function for spatial awareness, as originally suggested by the results of Doricchi and Tomaiuolo (2003) and Thiebaut de Schotten et al. (2005).

In support of this interpretation, another recent VLSM study on 80 stroke patients (Verdon et al. 2006) found that damage to

frontoparietal white matter fibers, which the authors identified with the pathway described by Thiebaut de Schotten et al. (Thiebaut de Schotten et al. 2005), correlated with the presence of generalized and severe neglect.

Relation to Spatial Working Memory Impairment

A cognitive function that could be particularly sensitive to frontoparietal disconnection is the building up and maintenance of memory for inspected spatial locations. In a series of studies, Husain et al. (2001) showed that neglect in cancellation tasks is significantly increased by the failure to remember the location of already canceled items. In a study addressing the anatomical correlates of poor spatial working memory (SWM) in neglect patients, Malhotra et al. (2005) concluded that "...a deficit in SWM would not be expected in all neglect patients, but it would be anticipated to occur in those who have damage to critical areas in the right parietal and frontal lobe that support SWM performance... lesion locations associated with the poorest SWM performance among neglect patients were *in right parietal white matter* and... the right insula. Damage to both these sites would be consistent with deafferentation and/or loss of cortical regions known to support SWM based on functional neuroimaging evidence" (Malhotra et al. 2005, p. 434, *our italics*). This conclusion clearly suggests the possibility that a lesion of the white matter can disrupt the whole frontoparietal network subserving SWM capacities.

Other Intrahemispheric Pathways

A recent anatomical investigation suggests that frontoparietal disconnection due to middle cerebral artery infarctions might not be the only type of intrahemispheric disconnection related to neglect. Bird et al. (2006) showed that in patients with infarctions in the territory of the right posterior cerebral artery, disconnection of white matter fiber tracts between the parahippocampal gyrus and the angular gyrus was correlated with left neglect. Interestingly, the authors also noted that when this type of intrahemispheric disconnection was coupled with lesions of the splenium of the corpus callosum (producing interhemispheric disconnection, see Interhemispheric Interactions and Disconnection below), neglect tended to be more severe.

Intrahemispheric Disconnection and Neglect: Discussion

Disconnection and Cortical Deactivation

Despite the abundant evidence reviewed above, an apparent challenge to the role of subcortical disconnection in the pathogenesis of neglect comes from a number of investigations on the correlation between levels of cortical perfusion and the presence of neglect in the acute, or hyperacute, poststroke phase. Using perfusion weighting imaging, based on estimates of arrival and clearance of a bolus of contrast indicating the level of functional activity in otherwise structurally spared cortical areas, Hillis et al. (2002) investigated the functional correlates of neglect and aphasia due to hyperacute (within 48 h from stroke) subcortical infarction. They found that, independent of the lesion localization (corona radiata or caudate/capsular structures), neglect was only present in patients who had associated cortical hypoperfusion and absent in those having no cortical hypoperfusion. Importantly, though only tested in aphasic patients, pharmacological or surgical intervention re-

storing cortical perfusion led to substantial improvement of cognitive impairments and prevented the development of cortical infarcts. This study shows that a lesion in the white matter does not necessarily cause neglect; however, no precise mapping of white matter lesions was made, thus leaving unexplored the relationship between lesion location and extent, cortical hypoperfusion and neglect. Notwithstanding this limitation, the findings by Hillis et al. (2002) are relevant in that they confirm that a subcortical disruption of frontoparietal connections, whether resulting from vascular damage (Doricchi and Tomaiuolo 2003), surgical section (Gaffan and Hornak 1997), or temporary/functional lesions (Thiebaut de Schotten et al. 2005), might cause neglect by reducing functional activity in the entire cortical-subcortical frontoparietal network connected by these pathways.

Following the terminology recently proposed by Catani and ffytche (2005), the present pathophysiological interpretation of the neglect syndrome emphasizes the combined role of "topological" factors, related to dysfunction of cortical specialized areas, and "hodological" factors, related to dysfunction of connecting pathways among the same areas. Furthermore, we propose that disconnection might produce more of a deficit than cortical damage/dysfunction alone through several, not mutually exclusive, mechanisms: 1) Damage to the tightly packed fibers of the white matter may result quantitatively more disrupting than damage to equivalent cortical volumes, by impairing the functioning of larger cortical areas (Fig. 3). 2) Brain networks are composed of cortical modules interacting with each other. Disturbed communication between modules might thus produce not only cortical hypofunctioning but also hyper- or inadequate functioning of several cortical areas, resulting in a more severe disintegration of complex functions than the deficit relative to lesion to isolated modules (Catani and ffytche 2005). 3) Cortical lesions may leave the possibility for other cortical areas to functionally compensate for the deficit, through the phenomena of brain plasticity (see, e.g., Duffau 2005); on the other hand, white matter damage, which provokes the dysfunction of a whole network of connected areas, might render compensation more difficult to obtain.

It remains to be seen whether frontoparietal disconnection is sufficient to produce signs of neglect, as suggested by some of the results reviewed here, or whether concomitant cortical damage is necessary. A prediction resulting from the first hypothesis is that patients with relatively pure white matter

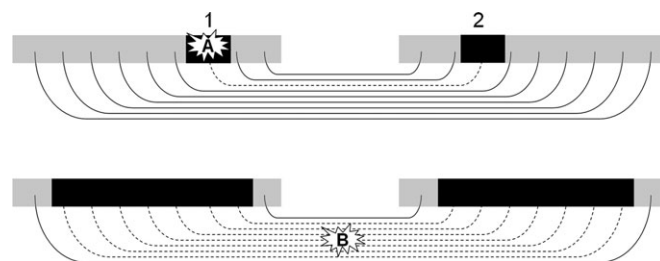


Figure 3. White matter lesions may cause more severe deficits than equivalent cortical lesions. Gray areas: functionally normal cortex. Black rectangles: dysfunctional cortical regions. Dashed pathways: dysfunctional white matter tracts. Lesion A to the cortical gray matter impairs cortical functions both 1) locally, through topological mechanisms, and 2) distally, through hodological mechanisms (see Catani and ffytche 2005). Lesion B, of equivalent volume but affecting the tightly packed white matter tracts, may impair the integrated functioning of larger cortical regions, thus resulting in a more severe deficit.

damage, resulting for example from multiple sclerosis or cerebral autosomal dominant arteriopathy with subcortical infarcts and leukoencephalopathy (CADASIL), may show signs of neglect. To the best of our knowledge, in the literature there are only a case report (Graff-Radford and Rizzo 1987) and a group study (Gilad et al. 2006) describing the possible occurrence of left neglect in patients with multiple sclerosis. Together with reports of patients with lesions of vascular origin, which affected primarily or exclusively the posterior limb of the right internal capsule (Healton et al. 1982; Ferro and Kertesz 1984; Ferro et al. 1987), this evidence does suggest the possibility of a purely disconnection basis of neglect. The apparently rare occurrence of neglect in diseases selectively affecting the white matter may depend on the frequently bilateral hemispheric involvement in these diseases, which may prevent unilateral neglect to occur (see the discussion on interhemispheric interactions in Neglect, Orienting of Attention and Interhemispheric Interactions: Callosal or Collicular? below), but probably also on the relative lack of interest for neglect of clinicians whom these patients are referred to. Signs of neglect may easily pass undetected without proper testing, as confirmed by the substantial lack of neglect literature before the mid-twentieth century. Only a systematic assessment of neglect in patients with selective damage of the white matter can shed light on this issue.

Perspectives for Neglect Research

The above reviewed evidence suggests that there are at least 2 long-range pathways linking the parietal to the frontal lobes whose dysfunction could be implicated in neglect (see Fig. 1). As previously mentioned, the inactivation of the SLF II in the right hemisphere causes rightward deviation on line-bisection tasks (Thiebaut de Schotten et al. 2005). Lesion of the more ventrally located SLF III in the right hemisphere correlates with rightward deviation on line-bisection and left omissions on visual search tasks (Doricchi and Tomaiuolo 2003). Although the combined lesion of these pathways might well generally disrupt the right hemisphere attentional networks (Corbetta et al. 2005), thus giving rise to generalized left neglect, future studies might be able to correlate selective lesions of one of these 2 pathways with particular patterns of functional deactivation in the cortex and behavioral dissociations in neglect symptoms. For example, the identification of white matter pathways disrupted in a particular patient, and the cortical areas consequently hypoactive even if undamaged (Corbetta et al. 2005), might help detailing the anatomical correlates of the many dissociations of performance described in neglect patients (near vs. far, perceptual vs. imaginal, etc.). Until now, the neural correlates of neglect dissociations have proved difficult to assess, perhaps because only gray matter lesions were considered. These considerations might prove important for patient diagnosis because a particular form of disconnection might have greater predictive value than the localization of gray matter lesions concerning the patients' deficits and disabilities. The demonstration of anatomically intact but functionally inactivated areas might also open perspectives for treatments (whether pharmacological or rehabilitative), aimed at restoring normal neural activity in these areas.

Implications for Theories of Neglect

The role of damage to different sectors of the cerebral networks linking the parietal and frontal lobes in the pathogenesis of unilateral neglect is currently a matter of intense debate.

One thesis proposes that the higher frequency, severity, and duration of left neglect after right brain damage, compared with right neglect after left brain damage, are due to the different competence of the 2 hemispheres in dealing with the left and the right side of space. According to this theory, the left hemisphere is able to represent only the right hemispace, whereas the right hemisphere is endowed with sensory-motor representations of both sides of space. Therefore, the higher frequency of neglect following right hemisphere damage is linked to the limited capacity of the left hemisphere in dealing with the left hemispace; conversely, the lower frequency of neglect after left hemisphere damage depends on the ability of the right hemisphere to deal with the whole horizontal space (Heilman et al. 1993; Mesulam 1999).

A second theory based on neuroimaging studies (Corbetta and Shulman 2002) holds that what is lateralized in the right hemisphere is not the sensory-motor representation of both hemispaces but, rather, a network including the IPL, the posterior part of the STG, the inferior and middle frontal gyri, and the frontal operculum, especially concerned with the detection of novel unexpected stimuli (such as those appearing at an unexpected spatial location following the presentation of an invalid spatial cue). This right hemisphere network triggers reorienting of attentional resources in dorsal bilateral networks including the superior parietal lobule and the frontal eye field (Corbetta et al. 2005). At variance with the previous hypothesis, Corbetta and co-workers surmise that each hemisphere is endowed with a dorsal network guiding endogenous orienting in the contralateral space and that the higher frequency of neglect following right hemisphere damage is due to the disruption of the alerting ventral network lateralized in the right hemisphere (Corbetta and Shulman 2002). A precise reconstruction of the section of the SLF damaged by the lesion causing neglect might therefore constitute a crucial test of these 2 hypotheses. Frontoparietal disconnection in the right hemisphere may disrupt the function of one or both of these networks or impair the integrated functioning of the 2 networks (Doricchi and Tomaiuolo 2003; Mort et al. 2003; Corbetta et al. 2005). For instance, showing that a selective lesion of SLF II, connecting the dorsal network, is sufficient to produce neglect signs would favor the first hypothesis, whereas linking neglect to a selective damage to the SLF III or the AF, connecting the ventral network, would be consistent with the theory of Corbetta and co-workers.

However, more complex anatomical-functional scenarios consistent with the heterogeneity of the neglect syndrome can be envisaged. For example, selective lesions of the different sectors of the SLF could be associated with different types of neglect or the presence of different neglect signs (e.g., behavioral dissociations in the performance of different tasks as, e.g., line bisection vs. multiple-item cancellation). We strongly argue that such a differential approach to the study of neglect syndrome could be by far more fruitful, from both clinical and theoretical standpoints, than trying to attribute neglect to the main influence of disruption of a single anatomical-functional brain module.

Interhemispheric Interactions and Disconnection

Neglect, Orienting of Attention and Interhemispheric Interactions: Callosal or Collicular?

Patients with left neglect typically show an asymmetry of attentional orienting, whereby orienting to right-sided objects

is easier and faster than orienting to left-sided objects (for review, see Bartolomeo and Chokron 2002). Thus, it has been suggested that left neglect essentially results from a rightward attentional bias (Kinsbourne 1970), from a deficit in disengaging attention from the right side to reorient it to the left side (Posner et al. 1984; Morrow and Ratcliff 1988), or from a deficit in orienting attention to the left contralesional hemisphere (Heilman and Valenstein 1979). A well-articulated account of neglect based on orienting of attention is the opponent processor model (Kinsbourne 1970, 1977, 1987, 1993). According to this hypothesis, each hemisphere shifts attention toward the contralateral hemisphere by inhibiting the other hemisphere. Moreover, in the normal brain there is a tendency to rightward orienting supported by the left hemisphere, which has a stronger orienting tendency than the right hemisphere. Right hemisphere lesions, by disinhibiting the left hemisphere, exaggerate this physiological rightward bias, thus giving rise to left neglect. Left neglect does not reflect an attentional deficit but an attentional bias consisting of enhanced attention toward the right. The verbal interaction between patient and examiner would further enhance left neglect by further activating the already disinhibited left hemisphere. Furthermore, left neglect patients would suffer from an abnormally tight focus of attention, which would deprive them of the possibility of a more general overview of the visual scene (Kinsbourne 1993). Right neglect would rarely be observed because much larger lesions of the left hemisphere are needed to overcome its stronger tendency to rightward orienting and because the verbal exchanges with the examiner would now work in the opposite direction, activating the left hemisphere and minimizing right neglect. Evidence supporting the opponent processor model came from the pioneering report of a patient who showed a severe left neglect following a first right-sided parietal infarct but abruptly recovered from neglect 10 days later, when he suffered from a second infarct in the dorsolateral frontal cortex of the left hemisphere (Vuilleumier et al. 1996). However, conclusive anatomical inferences from this case report seem not easy because the patient was studied in the acute phase of the disease, when transient phenomena of neural depression in areas remote from the lesion can occur (diaschisis; Meyer et al. 1993). As noted by the authors, the second stroke induced a tonic leftward deviation of head and gaze: this occurrence might have contributed to minimizing left neglect signs, similarly to the effects of vestibular or optokinetic stimulations (see Gainotti 1993; Vallar et al. 1997; Chokron and Bartolomeo 1999).

According to the opponent-processing model, increasing severity of neglect should result from an increasingly stronger bias toward the right, reflecting increasing disinhibition of the left hemisphere. Thus, response times to right-sided targets should become progressively faster as neglect increases in severity across patients. Contrary to this prediction, a group study of patients with varying degrees of neglect on paper-and-pencil tests demonstrated that not only patients' response times to left targets but also those to right targets increased with increasing neglect (Bartolomeo and Chokron 1999b). However, the 2 regression lines were not parallel. With increasing neglect, responses to left targets increased more steeply than those to right targets. Thus, a rightward attentional bias is present in patients with left neglect, together with left hypoattention. However, the rightward bias is one of the defective, and not enhanced, attention.

Full understanding of the interactions between the opponent processors in the 2 hemispheres requires the identification of neural mechanisms and pathways mediating such interactions. Mutually inhibitory interhemispheric interactions would intuitively appear to implicate the callosal connections; however, also the superior colliculi (SC), which mutually inhibit one another, are plausible candidates (Kinsbourne 1987). In the cat, lesion of one SC produces contralateral neglect, which can be reversed by lesion to the contralateral SC or by section of the intertectal commissure (Sprague 1966).

A more recent study (Rushmore et al. 2006) showed that ablation or cooling of the posterior parietal cortex induced contralateral neglect, which corresponded to decreased metabolic activity (as measured by 2-deoxyglucose uptake) of the ipsilateral SC and increased activity of the contralateral SC, but not of the contralateral parietal cortex; cooling of the opposite parietal cortex or SC restored orienting reactions to the previously neglected stimuli; and, correspondingly, collicular activity reverted to symmetry.

Weddell (2004) reported a possible human analogue of the Sprague effect (see also Zihl and von Cramon 1979). In a patient with a midbrain tumor, right frontal damage resulting from a surgical procedure provoked signs of left neglect, which disappeared abruptly 7 months later, when the tumor extended into the left SC. Most of the retinal afferents to the SC come from the contralateral eye. Thus, patching the right eye should decrease the visual input to the left SC, thereby decreasing its inhibition on the right SC. Consistent with the collicular hypothesis, neglect patients were found to show some improvement during the period when the patch was worn (Butter and Kirsch 1992). However, another study, contrasting monocular eye patching with patching of the 2 right visual hemifields that decreases the visual input to the left hemisphere, found an improvement of neglect only in the hemifield-patching group (Beis et al. 1999). Thus, a corticosubcortical system including both cortical and subcortical systems (respectively, the frontoparietal regions and the SC) might constitute the neural basis for the opponent processor model.

Results from transcranial magnetic stimulation (TMS) and functional magnetic resonance imaging (fMRI) studies in humans are also relevant for the opponent processor model. Oliveri et al. (1999) studied the effects of temporary inactivation by TMS of parietal and frontal sites in the intact hemisphere upon contralateral tactile extinction to bilateral simultaneous in right- and left brain-damaged patients. In right brain-damaged patients, TMS over the intact left frontal site significantly reduced extinction as compared with controls, whereas the same effect was not observed upon stimulation of the homologous site in the intact right hemisphere of left brain-damaged patients. These results are in keeping with the idea that TMS reduces inhibition from the stimulated to the unstimulated hemisphere and that mutual inhibition between the 2 hemispheres is asymmetrical, with more prominent inhibition directed from the left to the right hemisphere. Without excluding the possible contribution of subcortical mechanisms, the authors argued that TMS effects on extinction of tactile digit stimuli could have been well mediated by callosal fibers connecting "hand representations of associative parietal and frontal areas" as these connections "are more powerful and widespread than those between the primary hand motor and sensory areas" (p. 1737). As far as tactile modality is concerned, the authors further argued that this callosal mechanism might be particularly plausible because subcortical

mechanisms as the Sprague effect “seem to be valid especially for the visual system” (p. 1737).

A recent fMRI investigation (Corbetta et al. 2005) explored 11 stroke patients with left neglect who, in keeping with previous overlap studies (Doricchi and Tomaiuolo 2003; Mort et al. 2003), showed a maximal lesion overlap in the white matter beneath the IPL (see their Fig. 2 and the present Fig. 2). Four weeks after the stroke, when performing a response time task to lateralized stimuli, neglect patients had decreased activation of structurally intact frontoparietal regions in the right hemisphere (especially the intraparietal sulcus, the superior parietal lobule, and the dorsolateral prefrontal cortex), coupled with robust activation of the homologous regions in the left hemisphere. Thirty-nine weeks after lesion onset, recovery of neglect signs was paralleled by the disappearance of the imbalance between the 2 superior parietal lobules. According to the authors, this pattern of results suggests that lesions of the right TPJ determine a functional imbalance of the superior parietal lobules, which are structures important to attentional orienting. Consistent with the many previous findings and interpretations of neglect summarized in the present review, Corbetta et al. concluded that their results “rule out the possibility that neglect results from the critical dysfunction of one brain area” (p. 1608).

In conclusion, the reviewed evidence indicates that insight in the anatomical basis of the dynamic interplay between homologous structures in the 2 halves of the brain is of importance for the diagnosis and treatment of neglect and for the understanding of the mechanisms of spontaneous recovery or relevant clinical changes during the transition from the acute to the postacute and chronic phase.

Confabulations and Implicit Processing

Four decades ago, in his seminal review of disconnection syndromes, Geschwind (Geschwind 1965) suggested that some neglect signs reflected the activity of the left hemisphere being deprived of information from the right hemisphere. In Geschwind’s view, the left hemisphere is dominant not only for language but also for cognition in general; thus, if the right visual and somesthetic cortex are isolated from the left hemisphere, “[t]he left side of the body and of space is then ‘lost’. The patient will then respond in many instances by using [a] technique of confabulatory completion” (p. 600). These confabulatory responses would be the result of an isolated left hemisphere, with no access to the left-sided information processed by the right hemisphere. In other words, interhemispheric disconnection would produce a deafferentation of the left hemisphere, degrading the information coming from the left part of space, processed by the right hemisphere. To address the “vexing problem of why a left parietal lesion less often produces neglect of half space than does a right parietal lesion” (p. 601), Geschwind further proposed that “disease may simply aggravate the normal disadvantage of the right hemisphere in being further away and responding less well to stimuli” (p. 601), thus anticipating the above reviewed hypothesis later developed by Kinsbourne (see *Neglect, Orienting of Attention and Interhemispheric Interactions: Callosal or Collicular?* above).

Although the idea of a generally dominant left hemisphere is no longer accepted, other aspects of Geschwind’s proposal might help interpreting patterns of performance later described in split-brain patients and neglect patients. Following surgical

section of the corpus callosum, it has been reported that the left hemisphere sometime provides post hoc confabulatory verbal explanations of actions performed by the right hemisphere (Gazzaniga and Baynes 2000). In a well-known example (see Gazzaniga and Baynes 2000), a split-brain patient was shown tachistoscopically the pictures of a snow scene in the left visual field/right hemisphere and a rooster claw in the right field/left hemisphere. When the patient was presented with multiple pictures and asked to use each hand to choose those matching the bilateral displays, his right hand chose the picture of a rooster, and his left hand, driven by the right hemisphere, appropriately chose a shovel as a match for the snow scene. At debriefing, however, the patient, whose left hemisphere had not seen the snow scene, confabulated that the shovel was needed to clean out the chicken house.

Right brain-damaged patients with left-sided extinction or neglect may show remarkable implicit processing without overt verbal recognition of stimuli tachistoscopically presented in the left hemifield. Patients can perform better than chance when forced to make same/different judgments or to select in a multiple choice the identity of a nonexplicitly detected item (Volpe et al. 1979) and can show implicit semantic processing of the stimulus presented in the neglected hemifield (McGlinchey-Berroth et al. 1993; Berti et al. 1994), although only a minority of neglect patients may show such effects (D’Erme et al. 1993). One may also wonder whether any interhemispheric disconnection factors may contribute to the implicit processing and the confabulations concerning the neglected left side of visual stimuli presented in free vision. For example, in an often-cited case report (Marshall and Halligan 1988), patient P.S. was unable to tell the difference between 2 vertically arranged houses, one of which had its left side on fire. However, when asked in which of the 2 she would live, P.S. consistently chose the house that was not burning. In Geschwind’s view, this behavior could be accounted for by postulating 1) an inability of the left hemisphere to access left-sided information (the fire), with consequent lack of verbal acknowledgment of the difference between the 2 houses; 2) some residual (right hemisphere-based?) knowledge of this difference, either resulting in the appropriate behavioral choice or causing misinterpretation of the difference and resulting in a choice consistent with the misinterpretation. A further prediction coming from this hypothesis is that, if patients are asked “why” they prefer the nonburning house, their left hemisphere should either admit ignorance or produce confabulatory responses. In the case of P.S., no comments about her choices are available, except that she deemed “silly” the task of choosing between 2 “identical” houses. However, other studies provide this information and report a variety of responses at debriefing. For instance, a patient described by Manning and Kartsounis (1993) chose the non-burning house confabulating that it had an extra fireplace, consistent with Geschwind’s hypothesis. Another patient described by Bisiach and Rusconi (1990) consistently chose the “burning” house, considering it more “spacious” on the burning side, where the contour of the flames actually enlarged the shape of the house, an example of choice based on an implicit misinterpretation of the difference. In a group of 13 neglect patients (Doricchi et al. 1997), responses motivating correct implicit choices of the “non-burning house” were equally distributed into two categories: 1) “there is no specific reason for my choice, the 2 houses are the same anyway,” suggesting complete uncoupling of verbal output from

implicit processing; 2) “the house I chose is ‘better’, ‘bigger’, or ‘works better,’” suggesting, in this case, approximation of verbal output to implicit processing. Unfortunately, hypotheses on the functional and anatomical basis of the different examples of dissociation between explicit and implicit processing remain highly speculative because no related empirical evidence is currently available. Geschwind’s proposal of confabulatory responses resulting from an isolated left hemisphere indicates, however, possible ways to afford this fascinating puzzle.

Extinction

An important clinical phenomenon that has been interpreted in terms of interhemispheric disconnection is extinction after unilateral brain damage. Extinction refers to the failure of verbally reporting the most contralesional of a pair of simultaneous stimuli while maintaining an intact or largely preserved ability of reporting the same contralesional stimulus when presented alone. Extinction can occur both within and between different sensory modalities. It is often clinically detected in the recovery phase of neglect, though it can doubly dissociate from it. Marzi and co-workers (Smania et al. 1996) argued that right brain-damaged patients with extinction might suffer a partial interhemispheric disconnection syndrome, “whereby the information on the stimulus presented to the damaged right hemisphere cannot be efficiently integrated with that available to the left hemisphere” subserving the verbal response or mastering the task of deciding about the number of stimuli presented (“1” or “2”). These authors studied a right brain-damaged patient in whom disruption of interhemispheric transfer of visual information was demonstrated by recording of evoked potentials (Smania et al. 1996). In this patient, extinction of contralesional visual stimuli on double simultaneous presentation dropped dramatically when, instead of a verbal response (saying “2”), a motor response with no preferential triggering by one hemisphere (e.g., moving the eyes upward) or a response requiring bilateral muscular control (e.g., lowering the chin) was required to report double stimuli. According to the authors, when 2 stimuli are simultaneously presented to a right brain-damaged patient, the one perceived directly by the intact left hemisphere (dominating the verbal response) has stronger central representation, thus masking the weaker callosal input coming from the damaged hemisphere. In case of unilateral presentation to the damaged right hemisphere, the same callosal input triggers normal verbal recognition because no other stimulus competes for response in the left hemisphere. Impaired verbal report of stimuli arriving at the right hemisphere when simultaneously presented with stimuli to the left hemisphere was documented in a split-brain patient (Reuter-Lorenz et al. 1995). In line with the hypothesis that weak or impaired access to the responding hemisphere can modulate extinction and neglect phenomena, Corballis et al. (2005) recently described a callosotomized patient showing striking neglect for stimuli presented to the right hemisphere when these had to be reported verbally (i.e., by the left hemisphere). Neglect, however, disappeared when nonverbal responses were required, and the report was no more under the control of the left hemisphere. Thus, callosal damage might contribute, at least in some cases, to the appearance of split-brain-like confabulations or extinction of stimuli presented to the damaged hemisphere.

Anatomical Evidence Supporting the Influence of Interhemispheric Disconnection on Neglect

From an anatomical standpoint, the hypothesis of a contribution of interhemispheric disconnection to some of the behavioral features characterizing neglect has received empirical support from studies in animals and humans. Watson et al. (1984) found that on several behavioral measures (i.e., responses to auditory, visual, and somesthetic stimuli, circling behavior, and asymmetric orienting), postoperative neglect was more severe in monkeys that underwent callosotomy prior to ablation of the frontal arcuate gyrus as compared with monkeys that underwent only equivalent cortical ablation. Gaffan and Hornak (1997) showed that monkeys with combined resection of the right optic tract (causing complete left hemianopia) and the corpus callosum (causing complete interhemispheric forebrain disconnection) showed more severe neglect than monkeys undergoing section of frontoparietal connections (also causing substantial neglect, see Frontoparietal Disconnection and Spatial Neglect above) or resection of the parietal and/or prefrontal cortex (causing very mild and transitory neglect). The authors argued that severe neglect in monkeys with combined optic tract–callosal disconnection depended on the impossibility of the intact attentional frontoparietal system of the blind hemisphere to receive visual information gathered by the seeing hemisphere and to build up an adaptive compensatory mnemonic representation of the space contralateral to the blind hemisphere. In keeping with the proposal of Gaffan and Hornak, the defective integration of visual input from the intact left hemisphere with damaged mechanisms of space representation in the right hemisphere appears to produce erroneous compensation of the visual field defect in patients with neglect and concomitant hemianopia. This is revealed by horizontal distance-reproduction tasks forcing patients to set distance end points toward the attended or the otherwise spontaneously unattended hemispace (Bisiach et al. 1996; Doricchi and Angelelli 1999; Nico et al. 1999; Doricchi et al. 2005). In these tasks, the combination of neglect and hemianopia leads to marked and paradoxical hypometric distance reproductions in the ipsilesional direction (probably as a consequence of saccadic undershooting made in order to keep the endpoint from falling into the blind hemifield) and hypermetric responses in the contralesional direction (as a consequence of saccadic overshooting made to shift the blind hemifield away and bring the endpoint position into the seeing hemifield moving contralesionally; Ishiai 2002). Also in keeping with the findings of Gaffan and Hornak, the greater severity of neglect symptoms in patients with concomitant neglect and hemianopia, as compared with those with neglect unaccompanied by hemianopia, is well documented by studies from several laboratories and can be particularly evident in tasks requiring parallel processing of stimuli extending along the horizontal space such as, for example, the line-bisection task (D’Erme et al. 1987; Binder et al. 1992; Harvey et al. 1995; Bartolomeo and Chokron 1999a; Harvey and Milner 1999; Doricchi et al. 2005).

Results analogous to those obtained by Gaffan and Hornak with hemianopic-callosotomized monkeys were recently reported in human patients by Park et al. 2006, who found that among “. . . the various combinations of occipital plus adjacent lesions, only occipital injury together with complete injury to the splenium of the corpus callosum significantly contributed to the frequency and severity” of spatial neglect (p. 60). Park et al.

further observed that in their group of patients with unilateral damage in the territory of the posterior cerebral artery, visual field defects per se did not predict the severity of neglect. We notice, however, that the absence of a significant correlation between hemianopia and severity of neglect only reconfirms the well-established double dissociation between visual neglect and hemianopia (McFie et al. 1950; Gainotti 1968) and is not surprising to be found in a group of unselected right brain-damaged patients. In such an unselected group including hemianopic patients both with and without neglect, the compensatory leftward attentional bias of pure hemianopic patients (Fuchs 1920; D'Erme et al. 1987; Barton and Black 1998) will tend to cancel out the relationship between presence of hemianopia and severity of neglect that is observed when only patients with neglect are considered (Halligan et al. 1990; Gaffan and Hornak 1997; Doricchi and Angelelli 1999).

Finally, it is worth emphasizing that in patients with neglect, the influence of interhemispheric disconnection might be at work independently from the presence of concomitant visual field defect. Kashiwagi et al. (1990) described a patient who demonstrated left neglect signs after callosal infarction, with magnetic resonance imaging showing no lesion in the right hemisphere. This patient had neglect when performing paper-and-pencil tasks with his right hand but not when using his left hand (see also the already mentioned study by Corballis et al. 2005). More recently, the above reviewed lesion overlapping study by Doricchi and Tomaiuolo (2003) found that damage to callosal radiation can be a lesional correlate of chronic neglect unaccompanied by hemianopia.

In conclusion, though interhemispheric disconnection might not be a sufficient cause of neglect per se, as also suggested by the fact that split-brain patients do not systematically show signs of left neglect (Plourde and Sperry 1984; Gazzaniga and Baynes 2000), it could still explain some neglect-related phenomena. In this sense, the confabulations produced by split-brain patients and those generated by neglect patients might have at least partially superimposed functional causes, with the left hemisphere being totally deprived of right hemisphere processing in the first case or being provided with incompletely processed right hemisphere information in the second case.

Conclusion

A wealth of data from cognitive neurosciences indicate that the brain is a mosaic of functionally interconnected areas. The anatomical basis of these functional links begins now to be explored in detail (Mesulam 2005). Recent developments in neuroimaging techniques, such as DTI and fiber-tracking techniques, permit to map in vivo the white matter pathways, both in normal individuals (Catani et al. 2002) and in neurological patients (Thiebaut de Schotten et al. 2005). These new and exciting developments are likely to change our way of looking at brain-behavior relationships, for example, by giving the possibility of directly testing the disconnection hypotheses put forward by Geschwind (1965) 40 years ago (Catani and ffytche 2005), and more specifically, the interhemispheric disconnection hypothesis of neglect as well as the frontoparietal disconnection hypothesis reviewed here. Full consideration of the pathways of communication between functional regions of the brain will help avoid the risk of interpreting in a localist, "phrenological" way, patterns of performance which reflect instead the complexity of multiple, highly interactive processes.

Supplementary Material

Supplementary Material can be found at <http://www.cercor.oxfordjournals.org/>.

Notes

We thank Francesco Tomaiuolo and Maurizio Corbetta for providing us with details about their anatomical data, Marco Catani for very helpful discussion, and Serge Kinkingnehun and Cyril Poupon for help with neuroimaging processing. The Nuclear Magnetic Resonance database is the property of the Commissariat à l'Énergie Atomique, Service Hospitalier Frédéric Joliot, Unité de Neuro-imagerie Anatomofonctionnelle and can be provided on demand to cpoupon@shfj.cea.fr.
Conflict of Interest: None declared.

Address correspondence to Paolo Bartolomeo (Email: paolo.bartolomeo@chups.jussieu.fr) or to Fabrizio Doricchi (Email: fabrizio.doricchi@uniroma1.it).

References

- Azouvi P, Samuel C, Louis-Dreyfus A, Bernati T, Bartolomeo P, Beis J-M, Chokron S, Leclercq M, Marchal F, Martin Y et al. 2002. Sensitivity of clinical and behavioural tests of spatial neglect after right hemisphere stroke. *J Neurol Neurosurg Psychiatry*. 73(2):160-166.
- Bartolomeo P, Chokron S. 1999a. Egocentric frame of reference: its role in spatial bias after right hemisphere lesions. *Neuropsychologia*. 37(8):881-894.
- Bartolomeo P, Chokron S. 1999b. Left unilateral neglect or right hyperattention? *Neurology*. 53(9):2023-2027.
- Bartolomeo P, Chokron S. 2001. Levels of impairment in unilateral neglect. In: Boller F, Grafman J, editors. *Handbook of neuropsychology*. 2nd ed. Amsterdam (The Netherlands): Elsevier Science Publishers. p. 67-98.
- Bartolomeo P, Chokron S. 2002. Orienting of attention in left unilateral neglect. *Neurosci Biobehav Rev*. 26(2):217-234.
- Barton JJ, Black SE. 1998. Line bisection in hemianopia. *J Neurol Neurosurg Psychiatry*. 64(5):660-662.
- Basser PJ, Mattiello J, LeBihan D. 1994. Estimation of the effective self-diffusion tensor from the NMR spin echo. *J Magn Reson B*. 103(3):247-254.
- Bates E, Wilson SM, Saygin AP, Dick F, Sereno MI, Knight RT, Dronkers NF. 2003. Voxel-based lesion-symptom mapping. *Nat Neurosci*. 6(5):448-450.
- Beis J-M, Andre J-M, Baumgarten A, Challier B. 1999. Eye patching in unilateral spatial neglect: efficacy of two methods. *Arch Phys Med Rehabil*. 80(1):71-76.
- Berti A, Frassinetti F, Umiltà C. 1994. Nonconscious reading? Evidence from neglect dyslexia. *Cortex*. 30:181-197.
- Binder J, Marshall R, Lazar R, Benjamin J, Mohr JP. 1992. Distinct syndromes of hemineglect. *Arch Neurol*. 49(11):1187-1194.
- Bird CM, Malhotra P, Parton A, Coulthard E, Rushworth MF, Husain M. 2006. Visual neglect following right posterior cerebral artery infarction. *Journal of Neurology, Neurosurgery and Psychiatry*. 77: 1008-1012.
- Bisiach E, Pizzamiglio L, Nico D, Antonucci G. 1996. Beyond unilateral neglect. *Brain*. 119:851-857.
- Bisiach E, Rusconi ML. 1990. Break-down of perceptual awareness in unilateral neglect. *Cortex*. 26(4):643-649.
- Burcham KJ, Corwin JV, Stoll ML, Reep RL. 1997. Disconnection of medial agranular and posterior parietal cortex produces multimodal neglect in rats. *Behav Brain Res*. 86(1):41-47.
- Butter CM, Kirsch N. 1992. Combined and separate effects of eye patching and visual stimulation on unilateral neglect following stroke. *Arch Phys Med Rehabil*. 73(12):1133-1139.
- Catani M, ffytche DH. 2005. The rises and falls of disconnection syndromes. *Brain*. 128(Pt 10):2224-2239.
- Catani M, Howard RJ, Pajevic S, Jones DK. 2002. Virtual in vivo interactive dissection of white matter fasciculi in the human brain. *Neuroimage*. 17(1):77-94.
- Chafee MV, Goldman-Rakic PS. 2000. Inactivation of parietal and frontal cortex reveals interdependence of neural activity

- during memory-guided saccades. *J Neurophysiol.* 83(3):1550-1566.
- Chokron S, Bartolomeo P. 1999. Réduire expérimentalement la négligence spatiale unilatérale: revue de la littérature et implications théoriques. *Rev Neuropsychol.* 9(2-3):129-165.
- Colby CL, Goldberg ME. 1999. Space and attention in parietal cortex. *Annu Rev Neurosci.* 22:319-349.
- Committeri G, Pitzalis S, Galati G, Patria F, Pelle G, Sabatini U, Castriota-Scanderbeg A, Piccardi L, Guariglia C, Pizzamiglio L. 2007. Neural bases of personal and extrapersonal neglect in humans. *Brain.* 130(2):431-441.
- Corballis MC, Corballis PM, Fabri M, Paggi A, Manzoni T. 2005. Now you see it, now you don't: variable hemineglect in a commissurotomy man. *Cogn Brain Res.* 25(2):521-530.
- Corbetta M, Kincade MJ, Lewis C, Snyder AZ, Sapir A. 2005. Neural basis and recovery of spatial attention deficits in spatial neglect. *Nat Neurosci.* 8(11):1603-1610.
- Corbetta M, Shulman GL. 2002. Control of goal-directed and stimulus-driven attention in the brain. *Nat Rev Neurosci.* 3(3):201-215.
- D'Erme P, De Bonis C, Gainotti G. 1987. Influenza dell'emi-inattenzione e dell'emianopsia sui compiti di bisezione di linee nei pazienti cerebrosi [Influence of unilateral neglect and hemianopia on line bisection performance in brain-damaged patients]. *Arch Psicol Neurol Psichiatr.* 48:165-189.
- D'Erme P, Robertson IH, Bartolomeo P, Daniele A. 1993. Unilateral neglect: the fate of the extinguished visual stimuli. *Behav Neurol.* 6:143-150.
- Doricchi F, Angelelli P. 1999. Misrepresentation of horizontal space in left unilateral neglect: role of hemianopia. *Neurology.* 52(9):1845-1852.
- Doricchi F, Guariglia P, Figliozzi F, Silvetti M, Bruno G, Gasparini M. 2005. Causes of cross-over in unilateral neglect: between-group comparisons, within-patient dissociations and eye movements. *Brain.* 128(Pt 6):1386-1406.
- Doricchi F, Incoccia C, Galati G. 1997. Influence of figure-ground contrast on the implicit and explicit processing of line drawings in patients with left unilateral neglect. *Cogn Neuropsychol.* 14:573-594.
- Doricchi F, Tomaiuolo F. 2003. The anatomy of neglect without hemianopia: a key role for parietal-frontal disconnection? *Neuroreport.* 14(17):2239-2243.
- Duffau H. 2005. Lessons from brain mapping in surgery for low-grade glioma: insights into associations between tumour and brain plasticity. *Lancet Neurol.* 4(8):476-486.
- Ferro JM, Kertesz A. 1984. Posterior internal capsule infarction associated with neglect. *Arch Neurol.* 41(4):422-424.
- Ferro JM, Kertesz A, Black SE. 1987. Subcortical neglect: quantitation, anatomy, and recovery. *Neurology.* 37(9):1487-1492.
- Fuchs W. 1920. Untersuchung über das Sehen der Hemianopiker und Hemiamblyopiker. *Z Psychol Physiol Sinnersorg.* 84:67-169.
- Gaffan D, Hornak J. 1997. Visual neglect in the monkey. Representation and disconnection. *Brain.* 120(Pt 9):1647-1657.
- Gainotti G. 1968. [Les manifestations de négligence et d'inattention pour l'hémi-espace]. *Cortex.* 4:64-91.
- Gainotti G. 1993. The role of spontaneous eye movements in orienting attention and in unilateral neglect. In: Robertson IH, Marshall JC, editors. *Unilateral neglect: clinical and experimental studies.* Hove (UK): Lawrence Erlbaum Associates. p. 107-122.
- Gainotti G, D'Erme P, Bartolomeo P. 1991. Early orientation of attention toward the half space ipsilateral to the lesion in patients with unilateral brain damage. *J Neurol Neurosurg Psychiatry.* 54:1082-1089.
- Gazzaniga MS, Baynes K. 2000. Consciousness, introspection, and the split-brain: the two minds/one body problem. In: Gazzaniga MS, editor. *The new cognitive neurosciences.* Cambridge (MA): MIT Press. p. 1355-1363.
- Geschwind N. 1965. Disconnexion syndromes in animals and man—part II. *Brain.* 88:585-644.
- Gilad R, Sadeh M, Boaz M, Lampl Y. 2006. Visual spatial neglect in multiple sclerosis. *Cortex.* 42(8):1138-1142.
- Gitelman DR, Nobre AC, Parrish TB, LaBar KS, Kim Y-H, Meyer JR, Mesulam MM. 1999. A large-scale distributed network for covert spatial attention: further anatomical delineation based on stringent behavioural and cognitive controls. *Brain.* 122(6):1093-1106.
- Graff-Radford NR, Rizzo M. 1987. Neglect in a patient with multiple sclerosis. *Eur Neurol.* 26(2):100-103.
- Halligan PW, Marshall JC, Wade DT. 1990. Do visual field deficits exacerbate visuo-spatial neglect? *J Neurol Neurosurg Psychiatry.* 53(6):487-491.
- Harvey M, Milner AD. 1999. Residual perceptual distortion in 'recovered' hemispatial neglect. *Neuropsychologia.* 37(6):745-750.
- Harvey M, Milner AD, Roberts RC. 1995. An investigation of hemispatial neglect using the landmark task. *Brain Cogn.* 27:59-78.
- Healton EB, Navarro C, Bressman S, Brust JC. 1982. Subcortical neglect. *Neurology.* 32(7):776-778.
- Heilman KM, Valenstein E. 1979. Mechanisms underlying hemispatial neglect. *Ann Neurol.* 5:166-170.
- Heilman KM, Watson RT, Valenstein E. 1993. Neglect and related disorders. In: Heilman KM, Valenstein E, editors. *Clinical neuropsychology.* 3rd ed. New York (NY): Oxford University Press. p. 279-336.
- Hillis AE, Wityk RJ, Barker PB, Beauchamp NJ, Gailloud P, Murphy K, Cooper O, Metter EJ. 2002. Subcortical aphasia and neglect in acute stroke: the role of cortical hypoperfusion. *Brain.* 125(Pt 5):1094-1104.
- Husain M, Kennard C. 1996. Visual neglect associated with frontal lobe infarction. *J Neurol.* 243(9):652-657.
- Husain M, Mannan S, Hodgson T, Wojciulik E, Driver J, Kennard C. 2001. Impaired spatial working memory across saccades contributes to abnormal search in parietal neglect. *Brain.* 124(Pt 5):941-952.
- Husain M, Rorden C. 2003. Non-spatially lateralized mechanisms in hemispatial neglect. *Nat Rev Neurosci.* 4(1):26-36.
- Ishiai S. 2002. Perceptual and motor interaction in unilateral spatial neglect. In: Karnath HO, Milner D, Vallar G, editors. *The cognitive and neural bases of spatial neglect.* Oxford: Oxford University Press. p. 181-193.
- Karnath H-O, Ferber S, Himmelbach M. 2001. Spatial awareness is a function of the temporal not the posterior parietal lobe. *Nature.* 411(6840):950-963.
- Karnath H-O, Fruhmann Berger M, Kuker W, Rorden C. 2004. The anatomy of spatial neglect based on voxelwise statistical analysis: a study of 140 patients. *Cereb Cortex.* 14(10):1164-1172.
- Karnath H-O, Himmelbach M, Rorden C. 2002. The subcortical anatomy of human spatial neglect: putamen, caudate nucleus and pulvinar. *Brain.* 125(2):350-360.
- Kashiwagi A, Kashiwagi T, Nishikawa T, Tanabe H, Okuda J. 1990. Hemispatial neglect in a patient with callosal infarction. *Brain.* 113(Pt 4):1005-1023.
- Kinsbourne M. 1970. A model for the mechanism of unilateral neglect of space. *Trans Am Neurol Assoc.* 95:143-146.
- Kinsbourne M. 1977. Hemi-neglect and hemisphere rivalry. In: Weinstein EA, Friedland RP, editors. *Hemi-inattention and hemisphere specialization.* New York: Raven Press. p. 41-49.
- Kinsbourne M. 1987. Mechanisms of unilateral neglect. In: Jeannerod M, editor. *Neurophysiological and neuropsychological aspects of spatial neglect.* Amsterdam (The Netherlands): Elsevier Science Publishers. p. 69-86.
- Kinsbourne M. 1993. Orientational bias model of unilateral neglect: evidence from attentional gradients within hemispace. In: Robertson IH, Marshall JC, editors. *Unilateral neglect: clinical and experimental studies.* Hove (UK): Lawrence Erlbaum Associates. p. 63-86.
- LaBerge D. 2000. Networks of attention. In: Gazzaniga MS, editor. *The new cognitive neurosciences.* Cambridge (MA): MIT Press. p. 711-724.
- Leibovitch FS, Black SE, Caldwell CB, Ebert PL, Ehrlich LE, Szalaj JP. 1998. Brain-behavior correlations in hemispatial neglect using CT and SPECT: the Sunnybrook Stroke Study. *Neurology.* 50(4):901-908.
- Makris N, Kennedy DN, McInerney S, Sorensen AG, Wang R, Caviness VS Jr, Pandya DN. 2005. Segmentation of subcomponents within the superior longitudinal fascicle in humans: a quantitative, in vivo, DT-MRI study. *Cereb Cortex.* 15(6):854-869.

- Malhotra P, Jager HR, Parton A, Greenwood R, Playford ED, Brown MM, Driver J, Husain M. 2005. Spatial working memory capacity in unilateral neglect. *Brain*. 128(Pt 2):424-435.
- Manning L, Kartsounis LD. 1993. Confabulations related to tacit awareness in visual neglect. *Behav Neurol*. 6:211-213.
- Marshall JC, Halligan PW. 1988. Blindsight and insight into visuo-spatial neglect. *Nature*. 336:766-767.
- McFie J, Piercy MF, Zangwill OL. 1950. Visual spatial agnosia associated with lesions of the right hemisphere. *Brain*. 73:167-190.
- McGlinchey-Berroth R, Milberg W, Verfaellie M, Alexander M, Kiduff PT. 1993. Semantic processing in the neglected visual field: evidence from a lexical decision task. *Cogn Neuropsychol*. 10:79-108.
- Mesulam MM. 1981. A cortical network for directed attention and unilateral neglect. *Ann Neurol*. 10:309-325.
- Mesulam MM. 1985. Attention, confusional states and neglect. In: Mesulam MM, editor. *Principles of behavioral neurology*. Philadelphia (PA): F.A. Davis. p. 125-168.
- Mesulam MM. 1999. Spatial attention and neglect: parietal, frontal and cingulate contributions to the mental representation and attentional targeting of salient extrapersonal events. *Philos Trans R Soc Lond B Biol Sci*. 354(1387):1325-1346.
- Mesulam MM. 2005. Imaging connectivity in the human cerebral cortex: the next frontier? *Ann Neurol*. 57(1):5-7.
- Meyer JS, Obara K, Muramatsu K. 1993. Diaschisis. *Neurol Res*. 15(6):362-366.
- Milner AD, Goodale MA. 1995. *The visual brain in action*. Oxford: Oxford University Press.
- Mishkin M, Ungerleider LG, Macko KA. 1983. Object vision and spatial vision: two cortical pathways. *Trends Neurosci*. 6:414-417.
- Morecraft RJ, Geula C, Mesulam MM. 1993. Architecture of connectivity within a cingulo-fronto-parietal neurocognitive network for directed attention. *Arch Neurol*. 50(3):279-284.
- Morrow LA, Ratcliff G. 1988. The disengagement of covert attention and the neglect syndrome. *Psychobiology*. 16(3):261-269.
- Mort DJ, Malhotra P, Mannan SK, Rorden C, Pambakian A, Kennard C, Husain M. 2003. The anatomy of visual neglect. *Brain*. 126(Pt 9):1986-1997.
- Nico D, Galati G, Incochia C. 1999. The endpoints' task: an analysis of length reproduction in unilateral neglect. *Neuropsychologia*. 37(10):1181-1188.
- Oliveri M, Rossini PM, Traversa R, Cicinelli P, Filippi MM, Pasqualetti P, Tomaiuolo F, Caltagirone C. 1999. Left frontal transcranial magnetic stimulation reduces contralesional extinction in patients with unilateral right brain damage. *Brain*. 122(Pt 9):1731-1739.
- Park KC, Lee BH, Kim EJ, Shin MH, Choi KM, Yoon SS, Kwon SU, Chung CS, Lee KH, Heilman KM et al. 2006. Deafferentation-disconnection neglect induced by posterior cerebral artery infarction. *Neurology*. 66(1):56-61.
- Parton A, Malhotra P, Husain M. 2004. Hemispatial neglect. *J Neurol Neurosurg Psychiatry*. 75(1):13-21.
- Petrides M, Pandya DN. 2002. Association pathways of the prefrontal cortex and functional observations. In: Stuss DT, Knight RT, editors. *Principles of frontal lobe function*. Oxford: Oxford University Press. p. 31-50.
- Plourde G, Sperry RW. 1984. Left hemisphere involvement in left spatial neglect from right-sided lesions. *Brain*. 107(Pt 1):95-106.
- Posner MI. 2005. How I got here. In: Mayr U, Awh E, Keele SW, editors. *Developing individuality in the human brain: a tribute to Michael I. Posner*. Washington (DC): American Psychological Association. p. 328.
- Posner MI, Petersen SE. 1990. The attention system of human brain. *Annu Rev Neurosci*. 13:25-42.
- Posner MI, Walker JA, Friedrich FJ, Rafal RD. 1984. Effects of parietal injury on covert orienting of attention. *J Neurosci*. 4:1863-1874.
- Reep RL, Corwin JV, Cheatwood JL, Van Vleet TM, Heilman KM, Watson RT. 2004. A rodent model for investigating the neurobiology of contralateral neglect. *Cogn Behav Neurol*. 17(4):191-194.
- Reuter-Lorenz PA, Nozawa G, Gazzaniga MS, Hughes HC. 1995. Fate of neglected targets: a chronometric analysis of redundant target effects in the bisected brain. *J Exp Psychol Hum Percept Perform*. 21(2):211-230.
- Rizzolatti G, Matelli M. 2003. Two different streams form the dorsal visual system: anatomy and functions. *Exp Brain Res*. 153(2):146-157.
- Rushmore RJ, Valero-Cabre A, Lomber SG, Hilgetag CC, Payne BR. 2006. Functional circuitry underlying visual neglect. *Brain*. 129(Pt 7):1803-1821.
- Rushworth MFS, Behrens TEJ, Johansen-Berg H. 2006. Connection patterns distinguish 3 regions of human parietal cortex. *Cerebral Cortex*. 16:1418-1430.
- Schmahmann JD, Pandya DN. 2006. *Fiber pathways of the brain*. New York: Oxford University Press. 450 p.
- Selemon LD, Goldman-Rakic PS. 1988. Common cortical and subcortical targets of the dorsolateral prefrontal and posterior parietal cortices in the rhesus monkey: evidence for a distributed neural network subserving spatially guided behavior. *J Neurosci*. 8(11):4049-4068.
- Smania N, Martini MC, Prior M, Marzi CA. 1996. Input and response determinants of visual extinction: a case study. *Cortex*. 32:567-591.
- Sprague JM. 1966. Interaction of cortex and superior colliculus in mediation of visually guided behavior in the cat. *Science*. 153(743):1544-1547.
- Thiebaut de Schotten M, Kinkingnéhun SR, Delmaire C, Lévy R, Volle E, Dubois B, Lehericy S, Duffau H, Bartolomeo P. 2006. OVER-TRACK: A new tool to visualize the white matter organization in Talairach space. *Neuroimage*. 31(Supplement 1):S110.
- Thiebaut de Schotten M, Urbanski M, Duffau H, Volle E, Lévy R, Dubois B, Bartolomeo P. 2005. Direct evidence for a parietal-frontal pathway subserving spatial awareness in humans. *Science*. 309(5744):2226-2228.
- Vallar G. 2001. Extrapersonal visual unilateral spatial neglect and its neuroanatomy. *Neuroimage*. 14(1 Pt 2):S52-S58.
- Vallar G, Guariglia C, Rusconi ML. 1997. Modulation of the neglect syndrome by sensory stimulation. In: Thier P, Karnath HO, editors. *Parietal lobe contributions to orientation in 3D-space*. Heidelberg (Germany): Springer-Verlag. p. 555-578.
- Verdon V, Lovblad K-O, Hauert C-A, Vuilleumier P. Neuroanatomical basis of hemispatial neglect components using Voxel-based Lesion Symptom Mapping. 2nd Meeting of the European Societies of Neuropsychology; 2006 October 18-20; Toulouse, France. p 277.
- Volpe BT, Ledoux JE, Gazzaniga MS. 1979. Information processing of visual stimuli in an "extinguished" field. *Nature*. 282(5740):722-724.
- Vuilleumier P, Hester D, Assal G, Regli F. 1996. Unilateral spatial neglect recovery after sequential strokes. *Neurology*. 46:184-189.
- Watson RT, Valenstein E, Day AL, Heilman KM. 1984. The effect of corpus callosum lesions on unilateral neglect in monkeys. *Neurology*. 34(6):812-815.
- Weddell RA. 2004. Subcortical modulation of spatial attention including evidence that the Sprague effect extends to man. *Brain Cogn*. 55(3):497-506.
- Zihl J, von Cramon D. 1979. Collicular function in human vision. *Exp Brain Res*. 35(3):419-424.